

“You are receiving this monthly SonoPath.com newsletter on hot sonographic pathology subjects that we see every day owing to your relationship with a trusted clinical sonography service. This service has a working relationship with SonoPath.com and sees value in enhancing diagnostic efficiency in veterinary medicine.”

*Brought to by:*



**Animal Sounds**

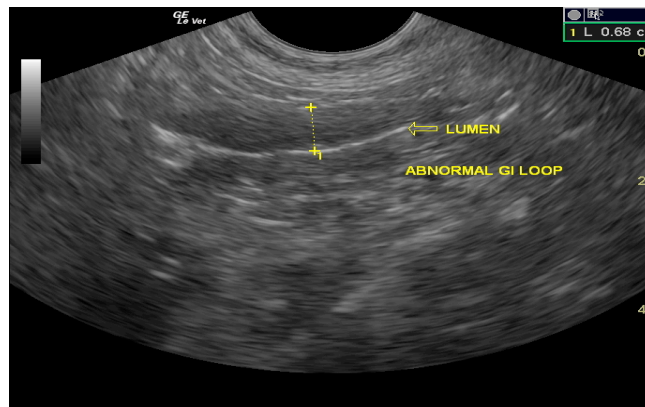
Mobile Veterinary Ultrasound Service

**Tomie Timon, RDMS**

541-357-9423

**April 2011**

## **Turning Dry-Form Feline Infectious Peritonitis (FIP) Inside Out With The Probe**



When I (Lindsey Daniel, DVM) found out that my first assigned topic was FIP, I figured that I was in obvious trouble with the boss. It has been a long time since I had researched this topic, mostly on purpose. When I think of my past dealings with FIP cases as a general and emergency practitioner in Georgia, no fond memories come to mind. My visions consist of very sick cats, with frustrated owners, upset that little could be done for treatment or diagnosis.

To start, I had to go back to the basics of the virus that causes FIP. Feline Infectious Peritonitis (FIP) is caused by a mutated form of the Feline Enteric Corona Virus (FECV). FECV is considered to be ubiquitous in the feline community. Most strains of the FECV are actually avirulent, so cats infected with them usually show no signs of disease. It is estimated that somewhere between 5-10% of cats infected with FECV will develop clinical FIP. Once FIP has developed, the virus is then referred to as Feline Infectious Peritonitis Virus (FIPV).

It is still not known why some cats will develop clinical FIP and others will not. Researchers speculate genetics, stress, number of cats in a household or cattery, and immune status all play a role. FECV is found in largest quantities in the saliva and feces, and is spread via a fecal-oral route. Despite this, FIPV is *not* considered to be highly contagious. It may take a cat weeks, months, and even years to develop actual FIP disease after the initial exposure to FECV, if they develop the disease at all. Most of us consider the disease to be more prevalent in young cats and kittens. However, this may not be the case based on our early findings in our current study on sonographic criteria of FIP in cats. Sadly, a patient I (LD) scanned last month was diagnosed with FIP at eleven years of age after intestinal biopsy. A quote from a virologist at the University of Tennessee, Melissa Kennedy, sums it up best by saying “it takes not only the ‘right virus’, but the ‘right cat’” to develop infection.

Some cats with FIP will exhibit no clinical signs. Others may exhibit non-specific signs such as fever, upper respiratory signs, diarrhea, weight loss, anorexia, and depression. FIP is characterized by two forms of disease, a “wet” or effusive form and

abdominal effusion (usually a modified transudate). The “dry” form has even been known to cause uveitis and seizures. Blood work abnormalities may, but not necessarily, include a non-regenerative anemia, neutrophilic leukocytosis, hyperproteinemia, hyperalbuminemia, and hyperglobulinemia.

In the May-June 2010 issue of JAAHA, Drs. Lewis and O’Brien at Kansas State published a study on the Abdominal Ultrasonographic findings in sixteen cats with confirmed FIP. They did not specify which form of FIP these cats had. Seven of the cats had peritoneal effusion, nine had abdominal lymphadenopathy, five had subcapsular rim signs in one or both kidneys, and five had liver lesions ranging from hypo to hyperechoic focal and diffuse lesions. Most of us are very comfortable with the presumptive signs of the “wet” form, namely the effusion. Sadly, the “dry” form is so much harder to differentiate from other diseases. We found very little research on this form in the journals, other than repeated mention that it tends to cause granulomatous lesions in various abdominal organs including the brain. In our experience, the intestinal presentation of the dry form FIP on ultrasound resembles intestinal neoplasia or severe IBD.

Take the case I mentioned in the second paragraph; “Smoke,” an 11-year-old, M/N, DSH indoor/outdoor cat. His presenting complaint was weight loss and anemia, and he was negative for FELV (+ for FIV from vaccination). On ultrasound, I found mesenteric lymphadenopathy, a thickened intestinal wall with loss of discernable wall layering in a GI loop (image above). However, there were no effusions in the abdomen or thorax. FNA of both the lymph nodes and the GI mass effect were inconclusive, so exploratory surgery and biopsies were performed by the regular veterinarian. Histopathology was both “characteristic and diagnostic” for FIP, however my primary differential was neoplasia such as Lymphoma. The pathologist at University of Georgia who read the case described the GI lesions (colon) and the lymph node as “granulomatous, multifocal, moderate; with necrosis”. The laboratory also performed Immunostaining for Feline Coronavirus on the colon, which was positive for FECV.

As for the dreaded topic of testing and treatment, unfortunately there is still no definitive pre-mortem test for FIP infection, other than histopathology. We can throw around all the fancy names like Elisa, PCR, and IFA, but none of them are 100% specific or sensitive for the clinical presence of FIP. These tests may support the presence of Feline Enteric Corona Virus Infection, but none can definitively diagnose FIP alone. The best pre-mortem test is still tissue biopsy. This may be obtained from an ultrasound-guided core biopsy procedure if a large enough target of pathology is available for the sonographer to sample. Otherwise, a surgical “shopping spree” of biopsies may be necessary if the clinical signs are present with only minor infiltrative GI pattern or aspecific sonographic findings in the liver, pancreas, or kidneys. In our experience, tissue biopsies are usually necessary (core US-guided biopsy or surgical wedge or punch biopsies, laparoscopy...) and fine needle aspirations are “suggestive for” diagnoses at best. Reason being, the pathologist usually needs to see the organization of the inflammatory elements in a granulomatous fashion in relationship to the infrastructure of the organ itself in order to have the best presentation to diagnose FIP as opposed to IBD or other inflammatory disease of the organ affected. Given that fine needle aspiration obtains cells only and not structure, cytology of the lesion is usually “hit or miss” regarding achieving a definitive diagnosis. Other practical factors of cytological versus histopathological determination depend on the experience of the cytologist reading the presentation, the cellular quality, and the clinical information provided. This being said, our (Lindquist & Team) personal preference is to read through the pathologist’s cytological description ourselves in addition to the pathologist’s “diagnosis” when evaluating the sample interpretation. This personal and subjective over reading of the cytology sample description, while pairing the findings with the sonographic and clinical information, as well as perhaps discussing the findings with the pathologist, will allow for a tertiary level evaluation of the case. This costs us only mental effort and a combination of subjective and objective evaluation. For further precision, this is why we usually provide a hard copy ultrasound image of the needle entering the lesion itself in order to pair the needle placement with the sonographically defined lesion. This demonstrates exactly what the needle was sampling at the time of the sonogram.

Given that lymphoma and carcinoma (the 2 primary differentials for intestinal mass or infiltrative lesions in addition to complex inflammatory lesion or FIP in a cat) have definitively different cellular presentations than the mixed inflammatory population present in an FIP sample, we can likely at least eliminate the probability of these 2 types of neoplasia causing the observed sonographic pattern. These lesions often “meet neoplastic criteria” on ultrasound. But as long as needle placement and proper sampling technique were utilized (i.e. reason for providing hard copy images of needle placement) we can surmise that the sample for the pathologist is representative of the pathology within reason. At this point if we reason through the case and ask ourselves the key question to every diagnostic dilemma “What Does This?” the thought process leaves us often in these cases with a diagnostic probability of a “complex inflammatory presentation with potential for FIP.” This deductive reasoning allows us to obtain a gut feeling on the case and target empirical therapeutic measures for inflammatory disease (broad spectrum antibiotics, B12, diet changes, prednisolone...) or again discuss obtaining a biopsy of the lesion.

**Intraoperative ultrasound** is also very helpful here to ensure that the surgical biopsies are taken of the most representatively dramatic lesion seen on ultrasound that may not be seen overtly from the surgical perspective unless macroscopic changes of the intestinal or other organ serosa is affected. Many of these FIP granulomatous lesions are intramural in the intestinal tract, or deep within the organ itself away avoiding detection from surgical view. For more on this technique see our abstract from ECVIM 2009 on Intraoperative Ultrasound in 3 Cats ([www.sonopath.com/resources](http://www.sonopath.com/resources)). Because of the practical difficulty in obtaining “shopping spree” surgical biopsies in vivo, many patients are diagnosed after necropsy. Because of this, diagnosis is often a presumptive one and should be suspected if traditional empirical treatments are not successful.

Similar to the dogma of FIP testing, there is also no proven successful treatment for FIP. FIP is still considered to be a progressive and fatal disease. However, given that the dry form of FIP is so diagnostically elusive, until we do more “shopping spree” sampling of these cases, we really don’t know how much FIP disease is really out there and how many cats are actually surviving a low grade clinical form of the disease. The most common forms of treatment we found on numerous posts on VIN

(besides supportive care) were Prednisolone (2-4 mg/kg/day PO, then taper every 2 weeks) and Pentoxifylline (*Trental*®, 100 mg PO BID). But these measures are empirically derived at best.

Currently, only one vaccine is available, Primucell-FIP® (intranasal), and it is not considered to be very effective. The American Association of Feline Practitioners' stand on FIP vaccination is quite clear as it is listed as "not generally recommended" in their vaccine guidelines. Dr. Fred Scott's research at Cornell Feline Health Center found the vaccine to not be highly effective, and therefore not recommended in low-risk populations. Because of this, prevention in high risk populations is reduced to good husbandry (i.e.: frequent litter box and cage cleaning) to help reduce the spread of the FECV. Even though FECV is stable in the environment for several weeks, it is susceptible to most cleaning products.

There is still so much we do not know about Feline Infectious Peritonitis. This makes our job of prevention, diagnosis, and treatment that much more difficult. Ultrasound can be very useful to diagnose lesions typically seen with disease, and aid in the obtaining of biopsies of affected tissues and fluid for analysis. To quote the University Of Tennessee Virologist Melissa Kennedy again, FIP is "a complex pathogenesis that is still being sorted out. When you think about how many Corona Viruses there are...yet only cats seem to manifest with this strange disease, it really is hard to understand".

***An example of a case of intestinal FIP that demonstrates the points made in this article may be found in this month's case of the month (April, 2011) at [www.SonoPath.com](http://www.SonoPath.com).***

Lindsey Daniel, DVM  
NJ Mobile Associate  
Owner/Co-operator Mobile Veterinary Ultrasound in Georgia  
[www.mobilevetultrasound.com](http://www.mobilevetultrasound.com)

Eric Lindquist DMV (Italy) DABVP,  
Cert. IVUSS  
Director SE NJ Mobile Associates  
Tel: 800 773 7944  
Founder SonoPath.com

#### References:

Addie, D. Belak, S. Boucraut-Baralon, C. Egberink, H. Frymus, T. Gruffydd-Jones, T...Horzinek, M. (July 2009). Feline Infectious Peritonitis ABCD Guidelines on prevention and management. *Journal Feline Medicine and Surgery*, 11(7), 594-604.

American Association of Feline Practicioners, [www.catvets.com](http://www.catvets.com)

Cornell Feline Health Center, [www.vet.cornell.edu/fhc](http://www.vet.cornell.edu/fhc)

Lewis, K.M. O'brien, R.T. (May-June 2010). Abdominal ultrasonographic findings associated with Feline Infectious Peritonitis: a retrospective review of 16 cases. *Journal of the American Animal Hospital Association*, 46(3), 152-160.

Plumb, D.C. *Plumb's Veterinary Drug Handbook*, 6<sup>th</sup> Edition, Blackwell Publishing, 2008.

Scott, F.W. Corapi, W.V. Olsen, C.W. (September 1992). Evaluation of the safety and efficacy of Primucell-FIP vaccine. *Feline Health Topics*, 7(3), 6-8.

University of Georgia College of Veterinary Medicine, Athens Diagnostic Laboratory, Pathology Report of the case mentioned is available upon request

[www.vin.com](http://www.vin.com) , search: FIP

Infectious Disease- Immunology Board, Melissa Kennedy, DVM, PhD, ACVM

Internal Medicine-Feline, Michele Gaspar, DVM, DABVP (Feline)

"Make every obstacle an opportunity." Lance Armstrong

This Communication has Been Fueled By



**SonoPath LLC.** 31 Maple Tree Ln. Sparta, NJ 07871 USA  
Via Costagrande 46, MontePorzio Catone (Roma) 00040 Italy  
**Tel: 800 838-4268**

For Case Studies & More Hot Topics In Veterinary Medicine For The GP & Clinical Sonographer Alike,  
Visit [www.SonoPath.com](http://www.SonoPath.com)